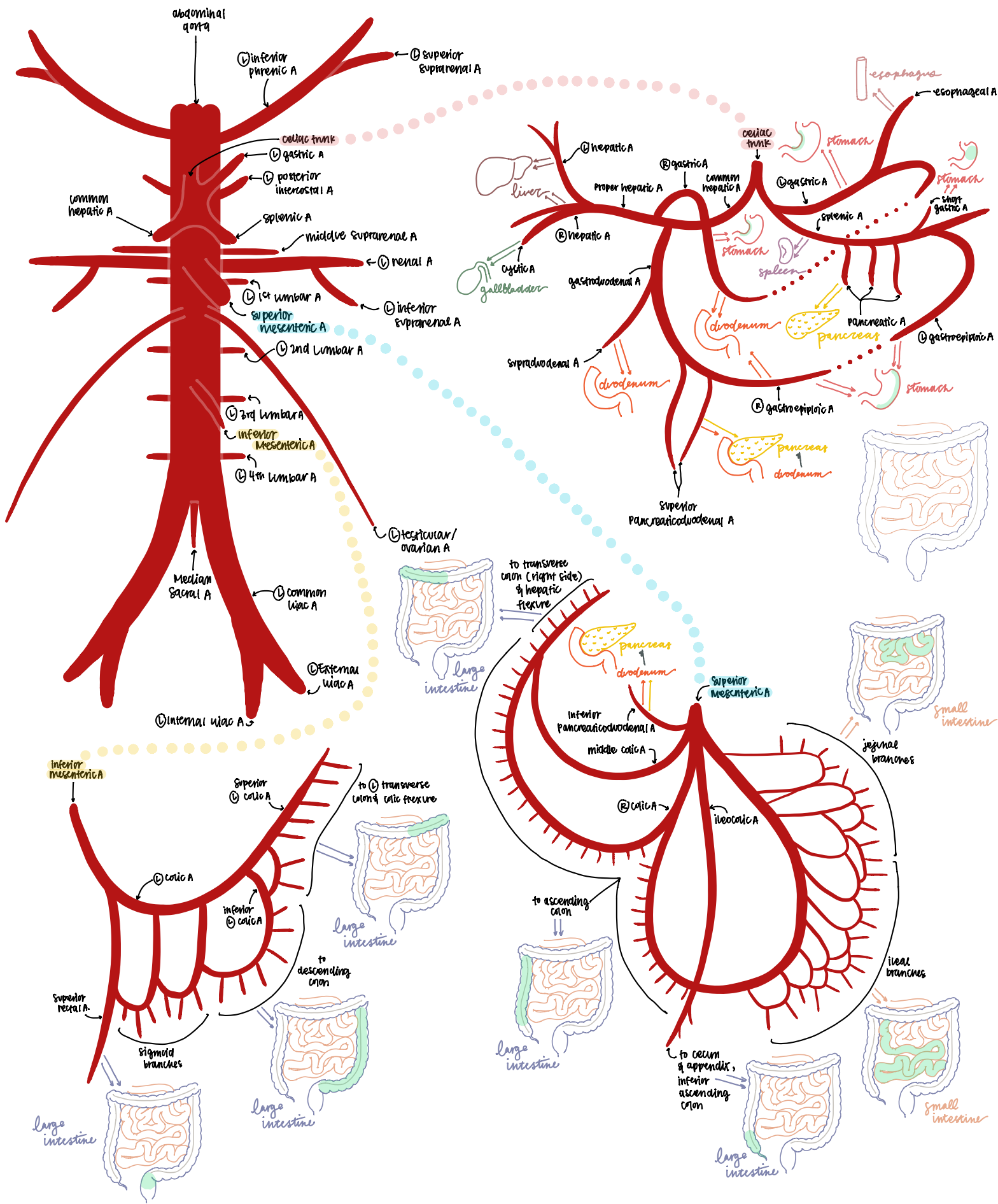



BLOOD SUPPLY





LIVER

- into liver
 - common hepatic A
 - ↳ proper hepatic A
 - ↳ (L) hepatic A
 - hepatic portal v
 - common bile duct
 - ↳ cystic duct
 - ↳ common hepatic duct
- ← out of liver
 - hepatic v
 - ↳ IVC

GALLBLADDER

- into gall bladder
 - cystic A
 - ↳ (R) hepatic A
 - ↳ proper hepatic A
 - ↳ common hepatic A
- ← out of gall bladder
 - cystic duct
 - ↳ common bile duct

STOMACH

- into stomach
 - (L) gastric A
 - ↳ celiac trunk
 - (R) gastric A
 - ↳ common/proper hepatic A
 - (L) gastropiploic A
 - ↳ splenic A
 - (R) gastropiploic A
 - ↳ gastroduodenal A
 - short gastric A → fundus
 - ↳ splenic A
 - ← out of stomach
 - (L) gastric v
 - ↳ hepatic portal v
 - (R) gastric v
 - ↳ hepatic portal v
 - (L) gastropiploic v
 - ↳ splenic v
 - (R) gastropiploic v
 - ↳ superior mesenteric v
- lesser curvature (L, R, short gastric A)
greater curvature (L, R gastropiploic A)

SPLEEN

- into spleen
 - splenic A
 - ↳ celiac A
- ← out of spleen
 - splenic v
 - ↳ hepatic portal v

PANCREAS

- into pancreas
 - pancreatic A
 - ↳ splenic A
 - superior pancreaticoduodenal A
 - ↳ gastroduodenal A
 - inferior pancreaticoduodenal A
 - ↳ superior mesenteric A
- ← out of pancreas
 - splenic v
 - ↳ hepatic portal v

ESOPHAGUS

- into esophagus
 - thoracic aorta
 - esophageal A
 - ↳ (L) gastric A
 - ↳ celiac trunk
 - ↳ inferior phrenic A
 - ↳ abdominal aorta
- ← out of esophagus
 - esophageal v
 - ↳ (L) gastric v
 - ↳ hepatic portal v

KIDNEYS

- into kidneys
 - superior suprarenal A
 - ↳ inferior phrenic A
 - middle suprarenal A
 - ↳ aorta
 - inferior suprarenal A
 - ↳ renal A
- ← out of kidneys
 - suprarenal v
 - ↳ (L) renal v → (L) kidney
 - ↳ IVC → (R) kidney

SMALL INTESTINES

- into small intestines
 - supraduodenal A
 - ↳ gastroduodenal A
 - superior pancreaticoduodenal A
 - ↳ gastroduodenal A
 - inferior pancreaticoduodenal A
 - ↳ superior mesenteric A
 - branches from (R) gastropiploic A
 - ↳ gastroduodenal A
 - branches from (R) gastric A
 - ↳ common/proper hepatic A
 - jejunal A → jejunum
 - ↳ superior mesenteric A
 - ileal A → ileum
 - ↳ superior mesenteric A
- ← out of small intestines
 - veins
 - ↳ superior mesenteric v
 - ↳ hepatic portal v

LARGE INTESTINES

- into large intestine
 - ileocolic A → ileocecal junction, cecum, appendix, inf ascending colon
 - ↳ superior mesenteric A
 - (R) colic A → ascending colon
 - ↳ superior mesenteric A
 - middle colic A → hepatic flexure & (R) transverse colon
 - ↳ superior mesenteric A
 - (L) colic A
 - ↳ inferior mesenteric A
 - sigmoid A
 - ↳ inferior mesenteric A
 - superior rectal A
 - ↳ inferior mesenteric A
- ← out of large intestine
 - veins
 - ↳ superior & inferior mesenteric v