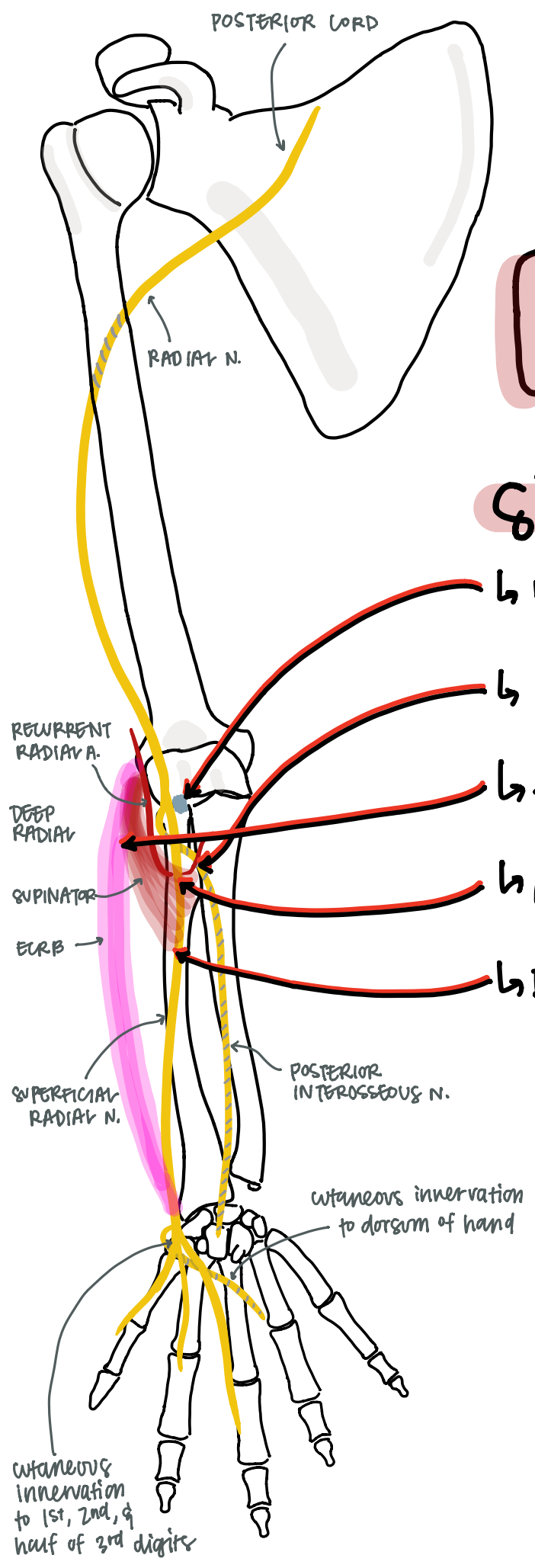


RADIAL

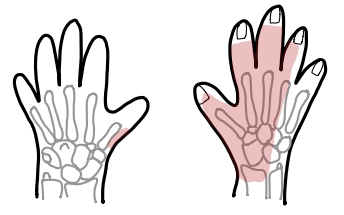
Sites of Entrapment:

- ↳ Radial Tunnel Fibrous Bands
 - ↳ anterior to radiocapitellar joint
- ↳ Leach of Henry
 - ↳ recurrent radial vessels over radial neck
- ↳ Edge of ECRB
 - ↳ proximal medial edge
- ↳ Arcade of Frohse ***most common**
 - ↳ superficial/proximal edge of supinator
- ↳ Distal edge of supinator



INNERVATIONS:

- Radial N.**
- Brachioradialis
 - ECRB
 - Anconeus
 - Triceps

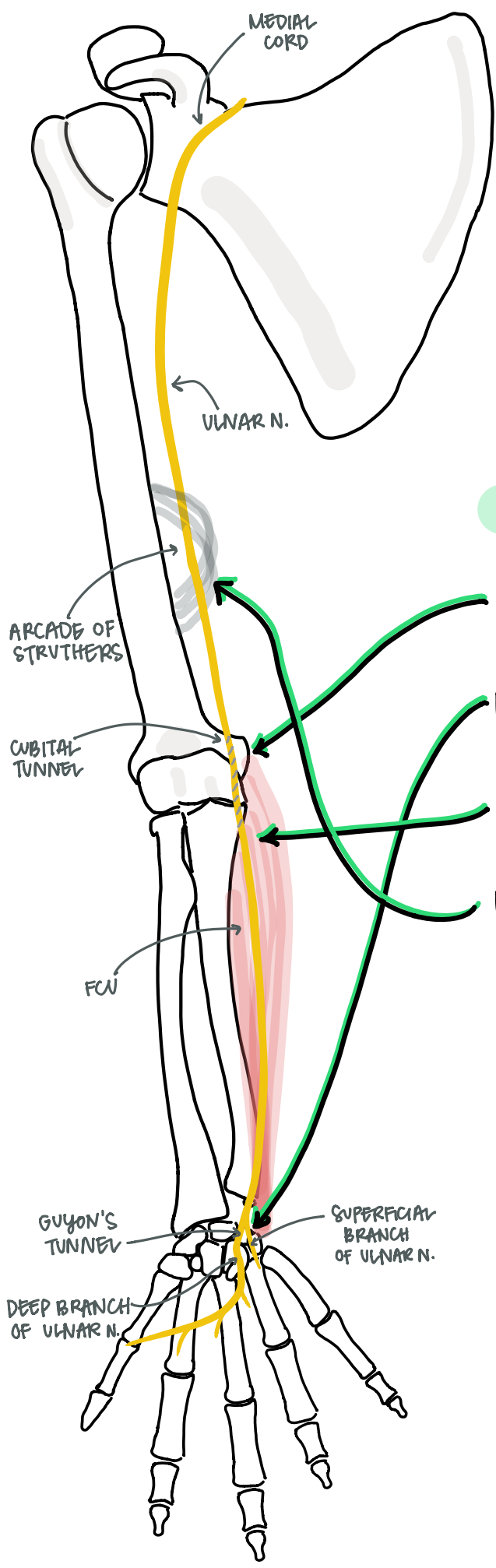


- Superficial radial N.**
- sensory to dorsum of digits 1, 2, 3, 1/2 4

- posterior / interosseous N.**
- | | | |
|-------------|-------|--------|
| - supinator | - EDI | - EPRB |
| - ECRB | - ECW | - EPL |
| - ED | - APL | - EI |

ULNAR

Sites of Entrapment:



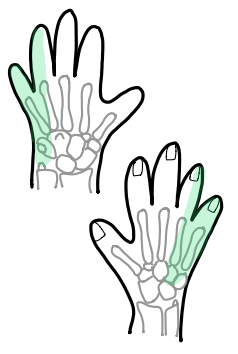
- ↳ Cubital Tunnel ** most common*
- ↳ Guyon's Tunnel
- ↳ Flexor forearm muscles - FCU
↳ between the 2 heads of FCU
- ↳ Arcade of Struthers

INNERVATIONS:

- Ulnar N.**
- FCU
 - FDP 3 & 4
 - sensory to digits 1/2, 4 & 5

- Superficial Ulnar N.**
- palmaris Brevis

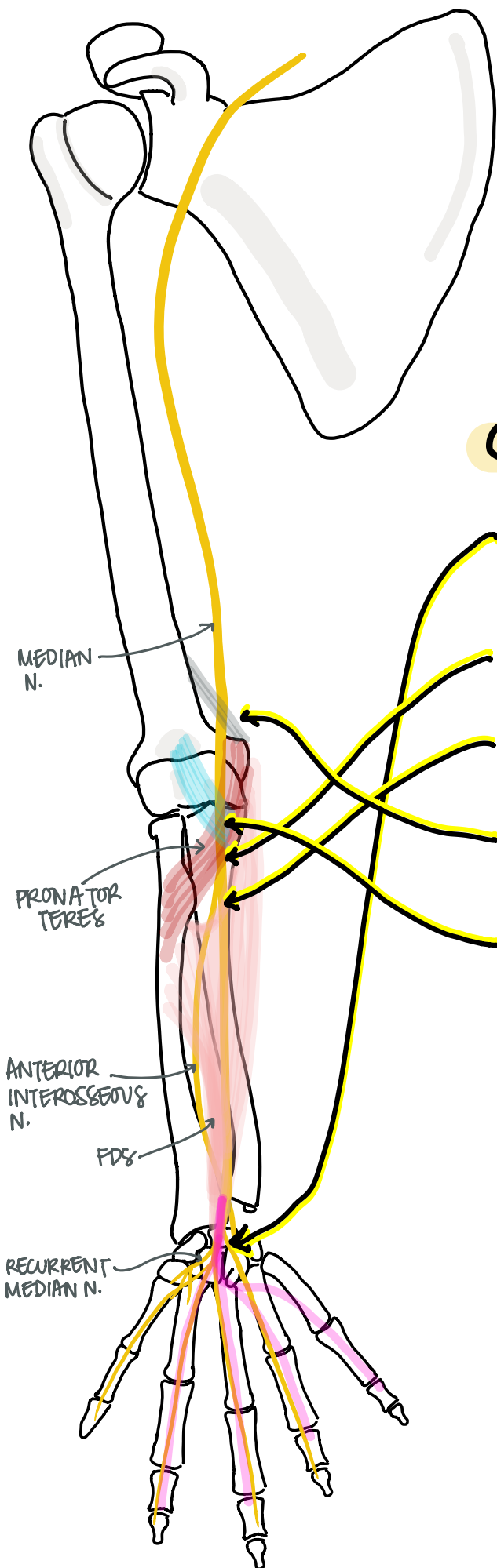
- Deep Ulnar N.**
- FPB - deep head
 - Adductor pollicis
 - palmar & dorsal Interossei
 - Lumbicals 3 & 4



- ODM
- ADM
- FDM

MEDIAN

Sites of Entrapment:

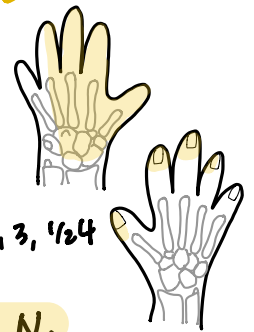


- ↳ Carpal tunnel * MOST COMMON
- ↳ pronator teres
 - ↳ between the 2 heads
- ↳ FDS
 - ↳ proximal fibrous arch of FDS
- ↳ Ligament of Struthers
- ↳ Lacertus fibrosus
 - ↳ bicipital aponeurosis

INNERVATIONS:

Median N.

- pronator teres
- FDS
- Lumbicals 1 & 2
- FCR
- Palmaris Longus
- Sensory to volar digits 1, 2, 3, 1/2 4



Anterior Interosseous N.

- FDP 1 & 2
- pronator Quadratus
- FPL

Recurrent Branch of Median N.

- OP
- APB
- FPB - superficial head